



MEIRAGTx

AAV-AIPL1 for the Treatment of Leber Congenital Amaurosis 4 (LCA4) Retinal Dystrophy

Alexandria Forbes, PhD, President and CEO

Professor Michel Michaelides, BSc, MB BS, MD(Res), FRCOphth, FACS
Professor of Ophthalmology & Consultant Ophthalmic Surgeon at UCL Institute of Ophthalmology and Moorfields Eye Hospital.

AIPL1 Retinal Dystrophy (LCA4)

- MeiraGTx's rAAV8.*hRKp.AIPL1* delivers the wild-type human *AIPL1* gene under control of a photoreceptor-specific rhodopsin kinase promoter, hRK. The product is administered subretinally.
- **To date, 11 children, 1 to 4 years old, have been successfully treated** with the rAAV8.*hRKp.AIPL1* drug product in the UK under an MHRA Specials Licence.
- Of the 11 treated patients:
 - The initial 4 patients received unilateral treatment - to ascertain safety and allow comparison with the untreated eye (Group 1).
 - 7 patients subsequently received bilateral treatment (Group 2).
- **There were no safety concerns in either of the patient groups.**
- **Efficacy has been observed in all 11 patients treated.**
 - In the unilateral-treatment group who were the first to be treated, **durable efficacy has been shown up to 4 years so far** (the longest follow up point).

Group 1: Unilateral Treatment Group

Improvements in Visual Acuity and Cortical Responses

Patient characteristics (visual acuity prior to intervention and at most recent assessment (Group 1 – unilateral surgery))

Child	Age (years) at intervention and follow up	Duration of follow up (years)	Visual Acuity		
			OD	OS	OU
1	2.6	Baseline	-	-	Follows light @ 10 cm
	6.7	4.1	0.80 LogMAR*	NPL [∅]	-
2	2.8	Baseline	-	-	Follows light @ 10 cm
	6.1	3.3	NPL [∅]	0.80 LogMAR*	-
3	1.0	Baseline	-	-	Follows light @ 20 cm
	4.3	3.3	Unmeasurable ^{®∅}	0.9 LogMAR*	-
4	2.1	Baseline	-	-	Follows light @ 50 cm
	4.4	2.3	Unmeasurable ^{®∅}	1.00 LogMAR*	-

LogMAR=logarithm of the minimum angle of resolution; NPL=no perception of light; OD=right eye; OS=left eye; OU=both eyes

* Treated eye

[∅] Untreated eye

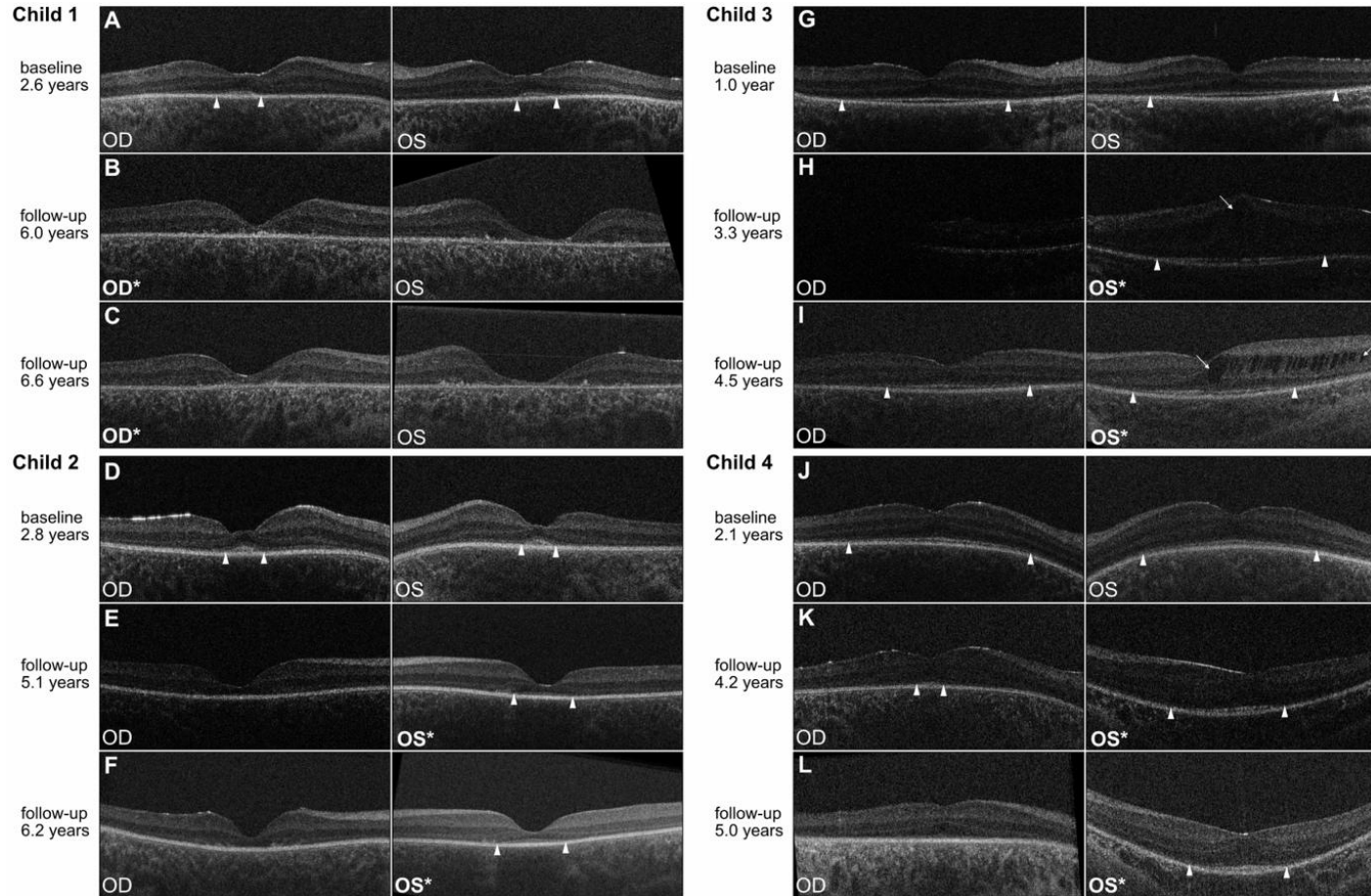
[®]Resists occlusion of the contralateral eye

- Binocular visual acuities prior to intervention were limited to perception of light.
- Patients have been followed for a mean of 3.5 years after intervention so far.
- **Benefit was observed in all 4 treated children**, with remarkable improvements in functional visual behavior, ability to record reliable visual acuities, reduced roving eye movements, and objective recording of vision driven brain activity with EEGs, as well as relative preservation of retinal structure in the treated eye compared to the untreated eye.
- **The visual acuities of patients' treated eyes improved to a mean of 0.9 LogMAR, with untreated eyes not improving**
- A second method of determining visual acuity, 'PopCSF', using a touchscreen-based test, also showed markedly improved performance in the treated eye when compared to the untreated eye. The visual acuity of the patients' untreated eyes was either unmeasurable or lacking perception of light.
- In addition, neurophysiology (cortical responses to visual stimuli; namely steady-state visually evoked potential [ssVEP] obtained from EEG) revealed retinocortical signal transmission selective to the treated eye. This demonstrates objective evidence of treatment benefit in visual perception.

Group 1: Unilateral Treatment Group

Improvements in Preservation of Retinal Structure

Retinal structure evaluated by hand-held OCT



Asterisks denote the treated eye. The extent of preserved outer retinal structure is labelled with white arrow heads. Cystoid macular oedema is indicated by white arrows. Years = age at time of OCT scan.

- OCT scans of the central retina for each child prior to intervention and at two time-points following treatment.
- **As detailed below, relative preservation of retinal structure was evident in the treated eye post-treatment and was generally not apparent in the untreated eye:**
 - **Child 1:** no clear preservation of outer retinal structure was evident in either eye after treatment. However, the central retinal thickness in their treated right eye appeared better-preserved than that of their untreated left eye.
 - **Child 2:** preservation of outer retina was evident in their treated left eye but was not apparent in their untreated right eye.
 - **Child 3:** preservation of outer retina was evident in their treated left eye. The outer retinal structure of their untreated right eye at 3.5 years after treatment appeared less well preserved than that of their treated left eye.
 - **Child 4:** areas of outer retinal preservation were evident in both eyes prior to treatment. The outer retina appeared better preserved in their treated left eye than in their untreated right eye after treatment.

Group 2: Bilateral Treatment Group Improvements in Visual Acuity and Cortical Responses

Visual acuities pre- and post-surgery (Group 2; Bilateral Surgery)

Subject no.	Visual acuity OD Pre-op	Visual acuity OD Post-op	Follow up OD surgery	Visual acuity OS Pre-op	Visual acuity OS Post-op	Follow up OS surgery	Visual acuity OU Pre-op	Visual acuity OU Post-op	Follow up OU surgery
			months			months			months
1	*	*	9	*	*	8.5	LogMAR 1.7	LogMAR 0.7	9
2	*	*	4.5	*	*	4	LP	LogMAR 1.3	4.5
3	HM	LogMAR 1.2	6	HM	LogMAR 1.4	1	HM	LogMAR 1.2	6
4	HM	LogMAR 1.2	1	HM	LogMAR 1.3	6	HM	LogMAR 1.2	6
5	*	LogMAR 0.6	6	*	LogMAR 0.6	5.5	LP	LogMAR 0.6	6
6	*	*	1.5	*	*	2	HM	LogMAR 1.5	2
7	*	*	1	*	*	1.5	LogMAR 1.3	LogMAR 0.8	1.5

HM=hand motion; LP=light perception; OD=right eye; OS=left eye; OU=both eyes;
*=unmeasurable

- Meaningful improvements were observed in all 7 bilaterally-treated children in functional vision, visual acuity, and neurophysiology revealing retinocortical signal transmission.
- The children's binocular visual acuities prior to intervention were limited to perception of light (2 children), motion (3 children) or recognition of high-contrast shapes (2 children; LogMAR 1.3 and 1.7).
- Children have so far been followed for a mean of 5 months after intervention.
- **The binocular visual acuities improved to a mean of 1.0 LogMAR.**

- » Children with *AIP1*-LCA4 are blind from birth. By age 4, retinal degeneration is complete.
- » Treatment with rAAV8.*hRKp.AIP1* in 11 children aged 1 to 4 years old has resulted in unequivocal improvements in visual function (more than or equal to 3 lines of visual acuity gain - often from light perception/hand motion detection to being able to record visual acuity – up to LogMAR 0.6), retinal function and visual behavior.
- » These improvements are unrivalled in treatment benefit compared to any ocular therapies, including any approved/published ocular gene therapy in any IRD.
- » These visual improvements in all 11 children have also resulted in life-changing benefits in all areas of development, including communication, behavior, schooling, mood, psychological benefits and social integration.
- » This is supported by videos from patients in both treatment groups, as well as family testimonials

- » Based on the strength of the data from the 11 children, MeiraGTx was awarded an Innovation Passport designation by the U.K. Innovative Licensing and Access Pathway Steering Group for rAAV8.*hRKp.AIPL1*.
- » Following a Scientific Advice meeting with the MHRA, MeiraGTx has been advised to file for 'Marketing Authorization Under Exceptional Circumstance' based on the current data from the 11 children treated, along with videos and interviews with patients and parents. No further clinical data is required and a CMC package to support approval has been aligned upon.
- » MeiraGTx is currently engaging with the FDA on a path forward for expedited regulatory approval in the United States.
- » AAV-AIPL1 has orphan status in the US and in the EU. It has also been given Rare Pediatric Disease Designation and as such is eligible for a PRV voucher on approval.
- » Discussions around addition of *AIPL1* to newborn testing panel underway.



Thank you